Section Editor: Gabor B. Racz, MD, FIPP

Cervical Spinal Canal Loculation and Secondary Ischemic Cord Injury—PVCS—Perivenous Counter Spread—Danger Sign!

Gabor B. Racz, MD, FIPP*; James E. Heavner, DVM, PhD, FIPP (Hon)†

**Texas Tech University Health Sciences Center, Lubbock, Texas; †Department of Anesthesiology, Texas Tech University Health Sciences Center, Lubbock, Texas, U.S.A.*

Editorial Note

This issue launches a new section in Pain Practice, Consultants' Corner—Primum Non Nocere. *In the context of evidence-based medicine (EBM), the content of this section should be viewed as expert opinion: advice from experienced consultants in pain medicine who, by virtue of their standing in the international medical community, have knowledge of a collective clinical experience far beyond their individual or institutional practices. The sharing of this experience in an ethical fashion should not be considered dogma, affect any ongoing litigation, or take the place of accepted EBM guidelines. Rather, this information is shared in the hope that patients may benefit from this "consultation" before a crisis arises:* primum non nocere. *CTH*

The goal of adding a *Consultants' Corner* to *Pain Practice* is to provide timely information that will help reduce complications that might occur when well-intentioned physicians provide care to patients. *Thou shall not have complications* is clearly the mantra. However, the practicing physician may not have information that could help meet this expectation even though the information exists. Such information may not be readily available to physicians who need it because it is very new and not widely known or well disseminated, is known by only a few, is considered privileged (eg, information associated with litigation), is published in obscure media, or for other reasons.

Consultants' Corner will shorten the time between when information becomes known or is needed and when it is available to the physician. Details will be omitted, as necessary, that breech confidentiality. The first *Consultants' Corner* article will spotlight new information about ways to avoid or reduce the incidence of a serious complication related to cervical epidural injections.

CERVICAL EPIDURAL INJECTIONS

Injections into the cervical epidural space is a recognized pain treatment modality. The injections may be single shot of local anesthetic and corticosteroid via needle or via catheter placement. The goal is to inject a high concentration of drug at the source of pain. Lysis of epidural adhesions that frees nerves for targeted drug delivery is part of the catheter technique (epidural neurolysis).[1–4] The capacity of the cervical peridural space to accommodate fluid is limited and becomes

Address correspondence and reprint requests to: Gabor B. Racz, MD, FIPP, Texas Tech University Health Sciences Center, 3601 4th Street, Lubbock, TX 79430, USA. E-mail: gbracz@yahoo.com.

DOI. 10.1111/j.1533-2500.2008.00228.x

© 2008 World Institute of Pain, 1530-7085/08/$15.00

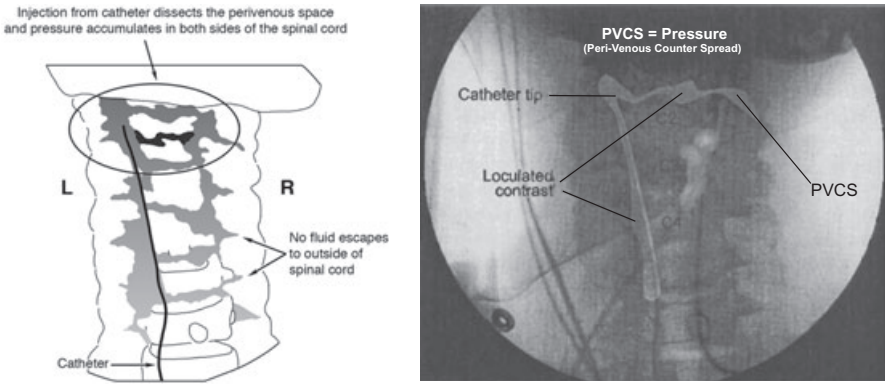

Figure 1. C3 cervical lysis of adhesions in the presence of C5-6 fusion following whiplash injury and C3 pain on left side; artist's drawing (left) and radiograph (right). Contrast injected through a catheter dissects the perivenous space, and pressure accumulates in both sides of the spinal cord. No fluid escapes outside of the spinal canal. Note the similarity of the perivenous left to right spread of contrast to the anatomical diagrams of ventral and dorsal venous plexuses (Figure 5).

more limited when the space is compromised by epidural scar formation, disk prolapse, trauma, surgery, or changes related to aging. When liquid is injected into this space, either by the transforaminal or interlaminar route, the goal is to have the drug flow in an unobstructed fashion to the target area. Even though small volumes are injected into the ventrolateral epidural space, fluid spread is rapid.[5] If the flow is obstructed, high pressures can be generated, and high pressures are the reason for this discussion. Assuring there is lateral transforaminal outlet flow may prevent subsequent ischemic changes. If the fluid does not flow and it becomes trapped in a closed compartment (loculation), the result may be pressure on the spinal cord, compromising the blood supply to the cord, producing ischemic and/or traumatic injury. There is some evidence that the epidural space normally has compartments, and when fluid is injected, it sequentially fills these compartments as the pressure in each compartment exceeds the pressure needed to break tissue barriers to intercompartmental flow.[6] Normally, the pressures that develop are inconsequential, but in the presence of pathology, the pressure can result in significant cord injury and neurological malfunction.

Fluid will follow the path of least resistance, which is unpredictable, especially if the epidural space is altered by, for example, fibrosis, and the resultant hydrostatic pressure becomes significant. Conscious patients who have no or minimal sedation will report rapid onset of bilateral arm pain that spreads to the chest and even to the lower extremities ("warning signs") when the pressure reaches a level that causes ischemia of the spinal cord.

These *warning signs* are absent in the unconscious patient. Nevertheless, how radiopaque contrast spreads (or does not spread) following cervical epidural injection, as observed under fluoroscopy, can also help identify entrapment of fluid in the unconscious as well as the conscious patient.

One great concern is when fluid spreads from the injection site to the opposite side of the spinal canal, and is prevented from spreading cephalad or caudad and through the neuroforamina, thus compressing the spinal cord from both sides (Figure 1). The sequence of events is predictable; the danger is from delayed recognition of this confined compartmental filling within the spinal canal.

When the loculation occurs and the patient complains of *warning signs* and the dye spread pattern is recognized, immediately flex and rotate the patient's head. Bring the chin to the shoulder, continuously flexing and rotating the head.[6] Movement of the patient's head and neck changes the size of the neuroformina; the foramina get larger on flexion and smaller on extension[7] (Figure 2). This increase in foraminal size is enhanced with flexion and rotation of the head. After moving the head as described, additional fluid injected should find the enlarged neural foramen, allowing the fluid to escape laterally (Figure 3). Push the catheter into the lateral neuroforamen, and inject additional fluid containing hyaluronidase to open the lateral recess and allow the fluid to escape outside the spinal canal. This releases the pressure, and the dangerous potential for ischemic and permanent or long-lasting cord injury changes may be prevented.

This initial observation was made and discussed in 2007.[8] However, the pattern of the spread from one side to the other and the precise location and structures involved were not previously recognized. The cervical venus plexus is less likely than the lumbar plexus to be

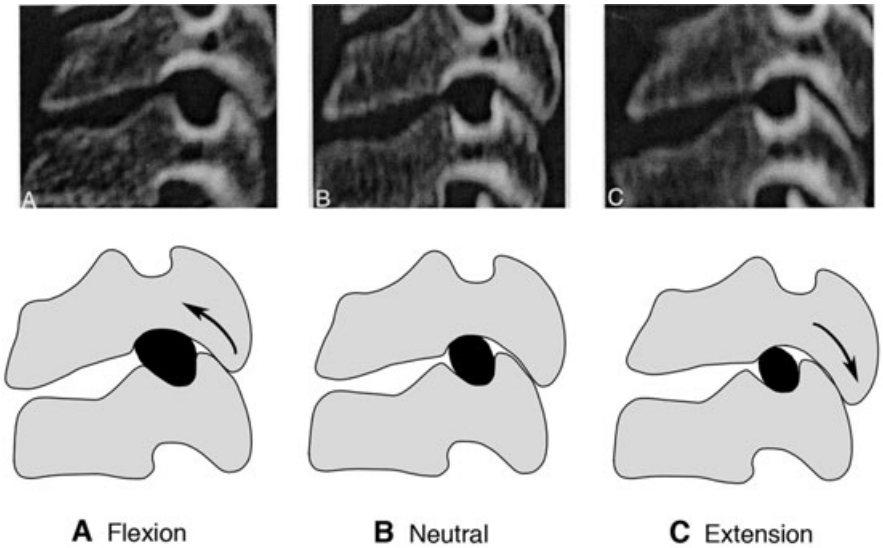

Figure 2. Changes in cervical neural foraminal size with flexion and extension (radiograph, upper images, based on Kitogana et al.[7]; artist's drawing, lower images). During flexion, the facet joint slides forward—foramen bigger. During extension, the facet joint slides backwards—foramen small.

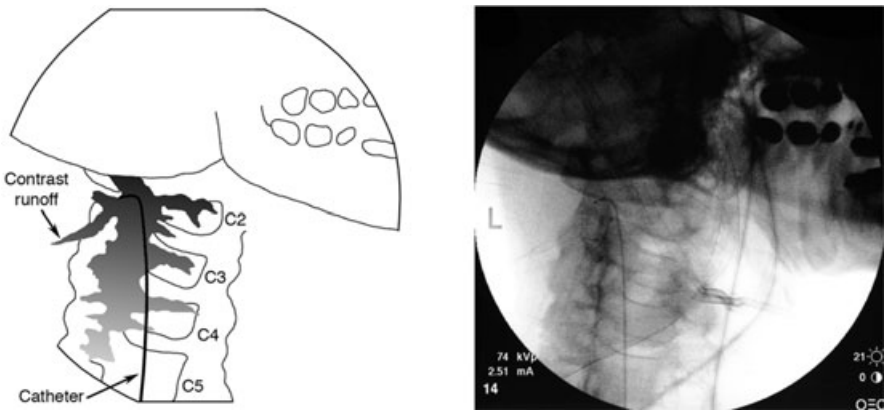

Figure 3. Flexion and rotation of the head and neck enlarges the neuroforamina, opening lateral runoff and decompression of pressure with immediate pain relief from reversal of pressure-induced ischemia.

penetrated by injected contrast from the pressure of the injection. The lumbar plexus shows distal venus runoff from the point of injection. The ipsilateral to contralateral flow of fluid follows a perivenous path in the epidural space. Evidence for this is the tortuous path contrast follows, corresponding to the course both veins take across the ventral cervical epidural space (Figure 1). The path is surprisingly torturous[9] (Figures 4 and 5). Fluid under pressure can open the perivenous space outside the veins going from one side of the spinal canal to the other, yet remains within the epidural space. The clinical scenario in the presence of the now-recognized *warning signs* in a patient who has no or minimal sedation will report rapid onset of bilateral arm pain spreading down to the chest and even to the lower extremity. Rotation of the head and neck and injection of additional fluid to induce runoff have resulted in virtually instantaneous disappearance of the pain produced by presumed spinal cord ischemia.

The clinical *warning signs* are not present if the patient is sedated, which can cause delayed recognition of the problem. After cervical injection, the patient wakening from the sedation, will complain of weakness, numbness, and pain, first on the maximally affected upper extremity, that progress to back pain in 15 to 20 minutes. Lower extremity weakness and paralysis, followed by increased upper extremity weakness and paralysis necessitating respiratory support may also occur. Precious time may be wasted getting a magnetic resonance imaging (MRI) and surgical consultation. Because there is no visible accumulation of blood, the condition may not be recognized on imaging as being due to small volume fluid loculation. Patients usually are treated with intravenous steroids, and over the next few days to weeks show recovery in multiple stages. The first MRI does not show changes, but a day or two later, MRI shows cord edema. The recovery can be almost complete with some residual changes in the maximal

Figure 4. Cervical spinal canal posterior dissection showing venous plexus in the posterior epidural space (Clemens 1961;[9] permission to reproduce sought through the following sources: (1) Walter de Gruyter, Inc: degruytermail@presswarehouse.com, (2) info@degruyterny.com; (3) Biomedical Information Services, docdelivery@hsc.unt.edu; (4) Interlibray Loan, illmail@hsc.unt.edu; and (5) Susan Warner at Covenant Hospital who secured the library loan of the book, swarner@covhs.net).

pressure area, which inevitably is the initial site of injection. Full recovery, with no MRI changes, no weakness, and no residual problems, was noted in the first scenario published.[8] Spread via the perivenous space without subsequent rotation of the head from side to side, not injecting additional fluid with hyaluronidase or local anesthetic with small particle steroid injection, may contribute to the development of the ischemic changes that can produce long-lasting complications.

An alternate scenario is when a cervical catheter is placed in the lateral epidural space and the first injection of contrast is into the lateral recess but there is no lateral runoff. The contrast spreads via the perivenous route to the opposite side, and loculation starts to occur on both sides of the spinal cord. The dye spread pattern of loculation is recognizable if looked for. If the patient is sedated and does not report pain, the next injection may be saline with hyaluronidase or local anesthetic and steroid, or saline and steroid, which may open the lateral runoff on the injection side but leaves the contrast on the contralateral side. As a result, ischemic changes occur from loculation on the side contralateral to the injection site. The pain, numbness, and motor deficit produced may take a long time to recover.

The described complications secondary to loculation following cervical epidural injections should be added to the list of risks associated with the injections, which include intra-arterial and intraneural injection, and injections into the spinal cord.[8] Seelander and Sjostrand[10] and Seelander et al.[11] predicted significant spinal cord injuries from intraneural small volume injections. The likelihood of intra-arterial and intraneural injections was shown to be exclusively sharp needle related in the animal model.[12,13] Virtually all intra-arterial and intraneural injection-related injuries to the spinal cord have been secondary to sharp needle use, recognizing that sharp needles are used in a high percentage of procedures. Not a single intra-arterial or intraneural injection-related myelopathy has yet been reported following the use of blunt needles. It was following a recent survey of cervical transforaminal injections by Scanlon et al. that the recommendation was made to use blunt needles to reduce the incidence of such occurrences.[14]

SUMMARY

Ipsilateral, bilateral, or contralateral loculation of injected fluid can occur following cervical epidural injections. When loculation occurs, there are warning signs, which include pain followed by weakness, numbness, and paralysis. Prompt action, including rotating the patient's head from side to side, and if catheter is used for the procedure, injection of additional volume of fluid containing hyaluronidase or local anesthetic and a small nonparticulate steroid mixture, such as dexamethasone, can be used to open the lateral runoff. Assure that the lateral runoff is established on both sides of the spinal cord, and pain, weakness, and numbness disappear. If sedation is used and the perivenous dye spread is noted, this should alert one to the possibility of increased pressure that may cause compression of the blood supply of the cord, and passive rotation may be recommended, although this has not been clinically tested. The suspicion for continuous loculation is raised if the patient in the postprocedure holding area reports back pain, lower extremity weakness, progressing to the development of quadriplegia. The usual workup and administration of intervenous steroids needs to proceed, because now one is dealing with a very difficult differential diagnosis. It is advisable to save the hard copy of fluoroscopic picture

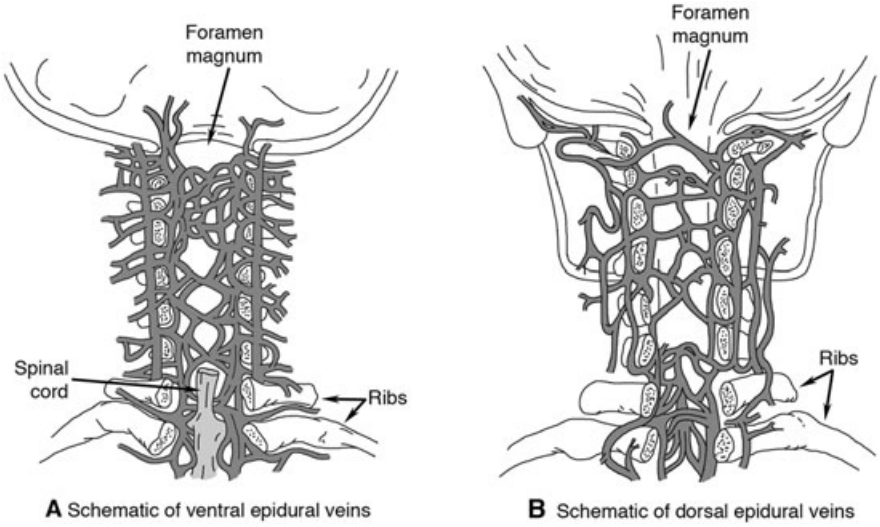

Figure 5. Schematic of anterior epidural veins (a) and dorsal epidural veins (b). In this artist's drawing, a complex venous plexus in the anterior as well as in the posterior epidural space is shown (based on Clemens 1961[9]).

of contrast injection. Then, if there is postprocedure pain, weakness, numbness, and paralysis, review of the dye spread may indicate the presence of loculation and pressure. Flexion, rotation, and stretching maneuvers may open up the lateral runoff, but this has not been clinically tested either.

There is support for the use of sedation to prevent patient movement and discomfort, but sedation needs should be carefully considered. If the decision is clearly in favor of using sedation, the radiographic danger sign may alert one to the possible development of this complication.

REFERENCES

1. Boswell MV, Shah RV, Everett CR, et al. Interventional techniques in the management of chronic spinal pain: evidence-based practice guidelines. *Pain Physician*. 2004;8:1–47.

2. Racz GB, Heavner JE, Trescot A. Lysis of epidural adhesions in evidence based medicine. *Pain Pract*. 2008;8:272–286.

3. Manchikanti L, Rivera J, Pampati V, et al. One day lumbar epidural adhesiolysis and hypertonic saline neurolysis in treatment of chronic low back pain: a randomized double blind trial. *Pain Physician*. 2004;7:177–186.

4. Veihelmann A, Devens C, Trouiller H, Birkenmaier C, Gerdesmeyer L, Refior HJ. Epidural neuroplasty versus physiotherapy to relieve pain in patients with sciatica: a prospective randomized blinded clinical trial. *J Orthop Sci*. 2006;11:365–369.

5. Kraemer J, Ludwig J, Bickert U, Owzarek V, Traupe M. Lumbar epidural perineural injection: a new technique. *Eur Spine J*. 1997;6:357–361.

6. Rocco AG, Philip JH, Boas RA, Scott D. Epidural space as a starling resistor and elevation of inflow resistance in a diseased epidural space. *Reg Anesth*. 1997;22:167–177.

7. Kitogana T, Fujiwara A, Kobayashi N, Saiki K, Tamai K, Saotome K. Morphologic changes in the cervical neural foramen due to flexion and extension (in vitro imaging study). *Spine*. 2004;29:2821–2825.

8. Racz GB, Heavner JE Complications associated with lysis of epidural adhesions and epiduroscopy. In: Neal JM, Rathmell JP, eds. *Complications of Regional Anesthesia and Pain Medicine*. New York: Elsevier; 2006:301–311.

9. Clemens H. *Die Venensysteme der Menschlichen Wirbelsaule. Morphologie and Functionelle Bedeutung*. Berlin: Walter de Gruyter & Co., plate 1; 1961.

10. Seelander D, Sjostrand J. Longitudinal spread of intraneurally injected local anesthetics. An experimental study of the initial neural distribution following intraneural injections. *Acta Anaesthesiol Scand*. 1978;22:622–634.

11. Seelander D, Dhuner KG, Lundborg G. Peripheral nerve injury due to injection needles used for regional anesthesia. An experimental study of the acute effects of needle point trauma. *Acta Anaesthesiol Scand*. 1977;21:182–188.

12. Heavner JE, Racz GB, Jenigiri B, Lehman T, Day M. Sharp versus blunt needle: a comparative study of penetration of internal structure and bleeding in dogs. *Pain Pract*. 2003;3:226–231.

13. Berger JJ, Hawkins IF. Celiac plexus block: use of a blunt-tipped needle. *Reg Anesth*. 1995;2(suppl 2):62.

14. Scanlon GC, Moeller-Bertram T, Renews SM, Wallace MS. Cervical transformational epidural steroid injections: more danger than we think? *Spine*. 2007;32:1249–1256.